

Dr. med. vet. Martin Deutschland MRCVS
Proskauer Strasse 29
10247 Berlin
Phone +49(0)176 67150024
Email mail@tierneurologie-berlin.de
Homepage www.tierneurologie-berlin.de



Magnetic Resonance Imaging Breeding Scheme Certificate

17 March 2017

Hereby I would like to confirm that **Anuka's Angel Annabella** was MRI examined at the Veterinary Surgery Dr. König, Hohenzollerndamm 114 A, 14199 Berlin. Date of examination: 13th March 2017.

Breeder/Owner [REDACTED]

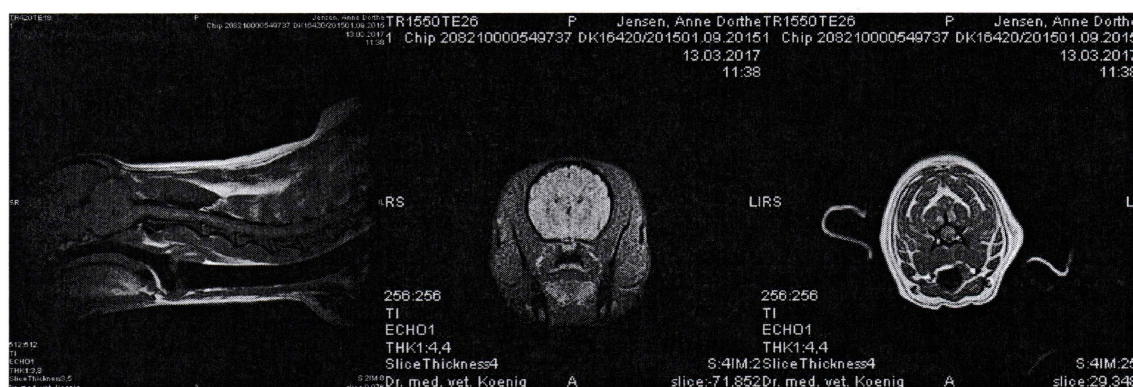
Breed CKCS **Date of Birth** 1st September 2015 **Sex** female **Colour** Ruby

ID-Chip-Number 208210000549737 **Kennel Club Number** DK16420/2015

Following results could be obtained:

Chiari-like Malformation (CM)	Grade 1-2
Enlargement of the Cervical Central Canal (Presyrinx)	not present
Syringomyelia	not present
Size and Symmetry of the Lateral Ventricle	symm.
Fluid Enhancement in the Middle Ear Cavity (PSOM)	not present

MRI-Pictures



The findings of this examination result in the following classification: **0c**. Please, visit www.tierneurologie-berlin.de/neurologische-erkrankungen/ for further information. According to the guideline of the British Veterinary Association and the Kennel Club (United Kingdom) the examined dog should only bred with individuals of the following classification: **0a, b, 1a**.

Dr. med. vet. Martin Deutschland MRCVS