

Cavalier King Charles Spaniel MRI evaluation report

Pedigree name: **Carasta Chipmunk Respect Said A.F.**

Registration number: **DK00162/2019** Gender: **Female**
 Microchip number: **208213990390041** Colour: **Black and Tan**
 Date of the MRI scan: **29-6-2020** Date of birth: **10-12-2018**
 Age at scanning: **1,55 years**

According to the submission form there were no neurological signs.

Age category: c

Based on the MRI scan send in the following grading is applicable:

Dutch Kennelclub / CCN / BVA / Kennelclub grading: CM Grade 2c / SM Grade 0c

Explanation:

CM grade 0	No herniation cerebellum	SM grade 0	No dilatation of the central canal or syrinx visible
CM grade 1	Herniation of the cerebellum but with minimal blockage of the CSF flow	SM grade 1	Dilatation of the central canal up to 2 mm
CM grade 2	Herniation of the cerebellum and with complete blockage of the CSF flow	SM grade 2	Dilatation of the central canal of 2 mm or more, or a syrinx is visible.

Additional information on the ventricular system get grade 2. The middle ear on the left side showed 0 and the middle ear on the right side 0.

Concerning (microchip) artefacts the grading is 1. Any grading above 1 means that the quality of the scan is of such a quality that the final result could not be estimated and that the current grading could be an underestimate of the real situation.

Explanation:

Ventricular system	Artefacts?	Middle ear
0 = no abnormalities	0 = none	0 = not visible
1 = dilatation of the 4th ventricle	1 = not severe	1 = only a limited amount of material is visible
2 = mild dilatation	2 = too severe to evaluate	2 = there is material visible
3 = severe dilatation of the ventricles		3 = the bullae are completely filled with material

Signed by



Dr. Paul Mandigers
 DVM, PhD, Diplomate ECVN
 Diplomate RNVA Internal Medicine
 European Specialist Veterinary Neurology EBVS

Cavalier King Charles Spaniel MRI evaluation report

Pedigree name: **Carasta Chipmunk Respect Said A.F.**

Registration number: **DK00162/2019**
 Microchip number: **208213990390041**
 Date of the MRI scan: **29-6-2020**
 Age at scanning: **1,55 years**

Gender: **Female**
 Colour: **Black and Tan**
 Date of birth: **10-12-2018**

Extra information concerning the MRI scan. This information is additional information and could be of use for breeding selection.

*Utrecht grading of the herniation is grade **2** and the shape of the cerebellum get grade **0***

Chiari malformation grading	Shape
0 = grade 0	0 = not abnormal
1 = grade 1 as the UK system	1 = the cerebellum is clover leaf shaped
2 = grade 2 as the UK system	2 = the cerebellum is flattened at the front side
3 = grade 2 and added to this the herniation and indentation is clearly visible	3 = the cerebellum is flattened at the hind side
4 = grade 2 and added to this the herniation and indentation is severe	4 = Subtentorial herniation is seen
	5 = Abnormal shape not listed above

Utrecht information concerning the spinal cord:

The visibility of the central canal on the sagittal T2 weighted and transverse T1 weighted images gets grade **0**, whereas the sagittal T1 weighted images gets grade **0**. The shape of the dilatation or syrinx gets grade **0**. We could see the central canal according to grade **0**. The maximum internal diameter of the dilatation measures **0** mm. The Belgium classification is **Categorie 1**

Visibility sagittal T2 & transversal T1	Visibility sagittal T1	Shape of the central canal or the syrinx	Visible from ... To	Diameter in millimetres
0 = not visible	0 = not visible on T1	0 = not or circular	0 = not visible	
1 = visible sagittal T2	1 = visible on the T1 sagittal	1 = presyrinx	1 = sagittal T1 from to	
2 = visible S-T2 en TV T1		2 = CC open to dorsal	2 = sagittal T2 from to	
3 = visible 1-2 mm TV T1		3 = CK asymmetrical to aside		
4 = visible 2-3 mm TV T1		4 = separate syrinx		
5 = visible 3-4 mm TV T1				
6 = visible > 4 mm TV T1				

Perviously used UK classification: **C**

Concerning (microchip) artefacts the grading is **1**.

Signed by

Dr. Paul Mandigers

DVM, PhD, Diplomate ECVN
 Diplomate RNVA Internal Medicine
 European Specialist Veterinary Neurology EBVS



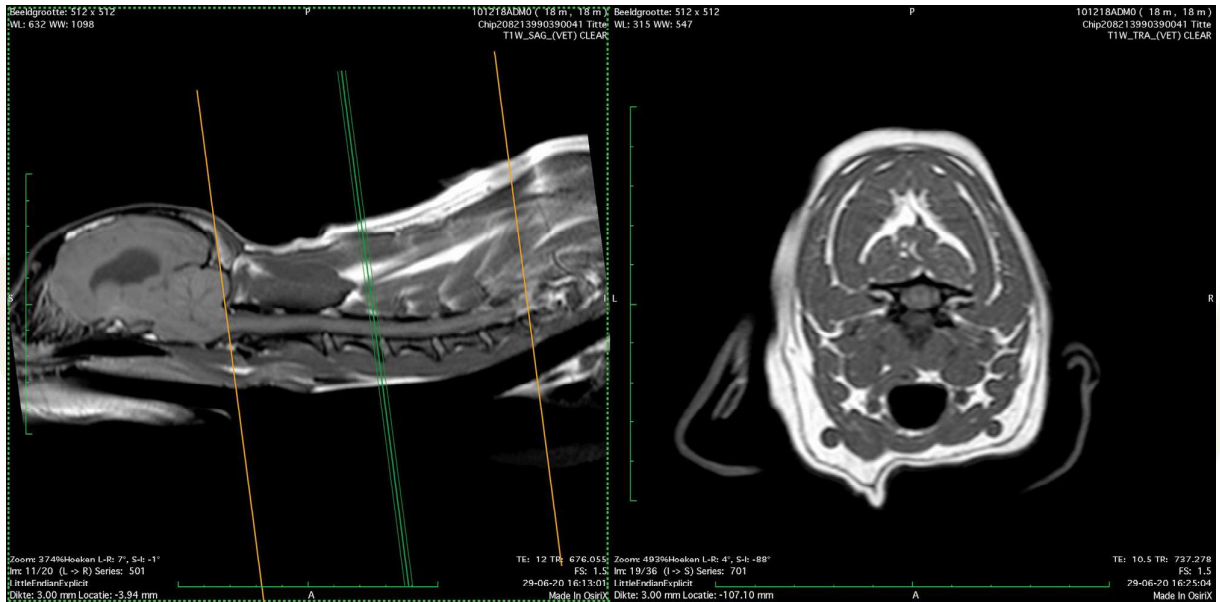
Cavalier King Charles Spaniel
Extra information about the MRI scan

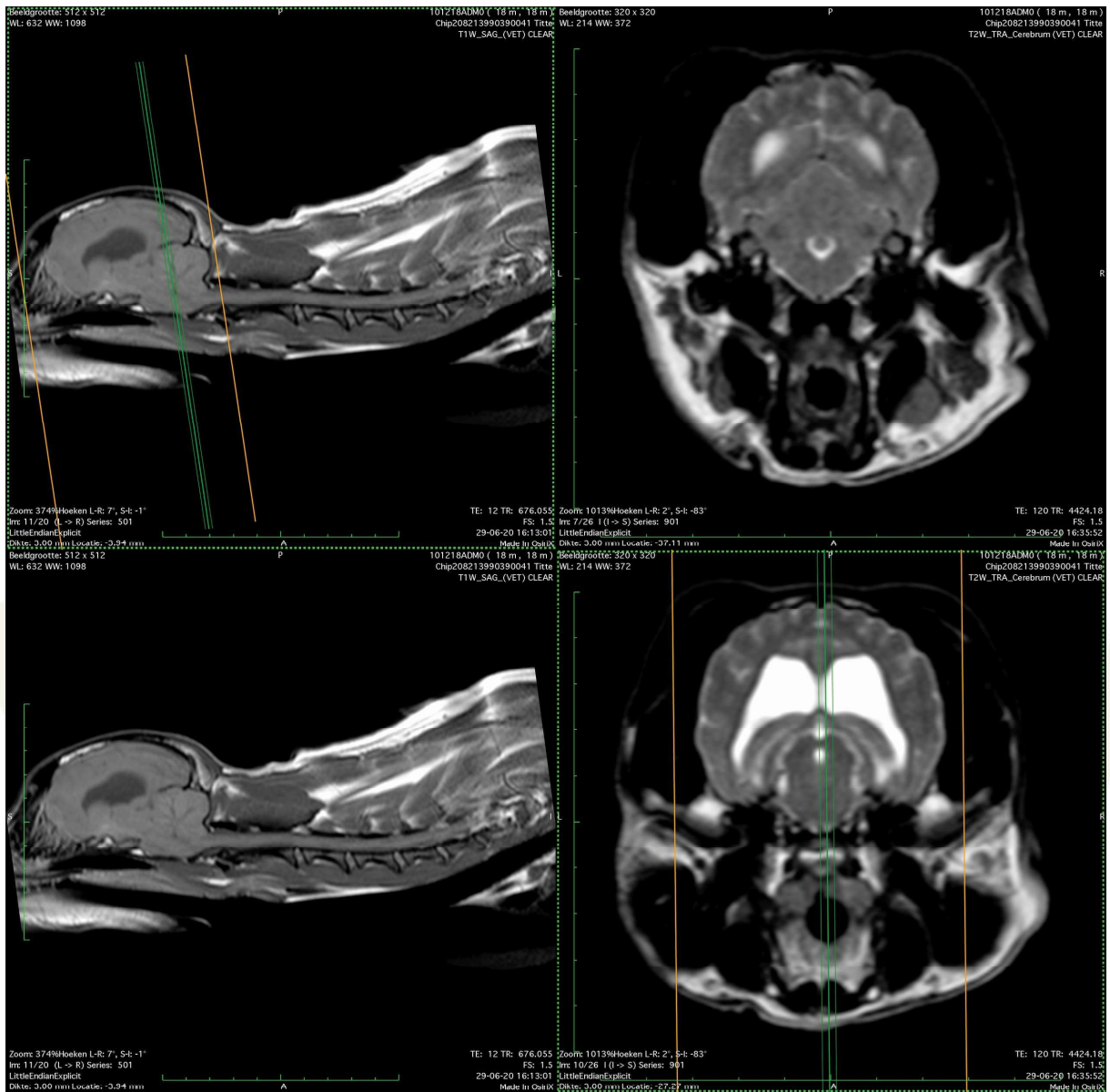
Pedigree name: **Carasta Chipmunk Respect Said A.F.**

Registration number: **DK00162/2019**
Microchip number: **208213990390041**
Date of the MRI scan: **29-6-2020**
Age at scanning: **1,55 years**

Gender: **Female**
Colour: **Black and Tan**
Date of birth: **10-12-2018**

Pictures from the MRI scan:





For any questions or other queries you are kindly asked to use this reference number: MJUL2020-4.
The MRI scan has been produced by mr / dr / clinic Mr-Scanner.dk.